

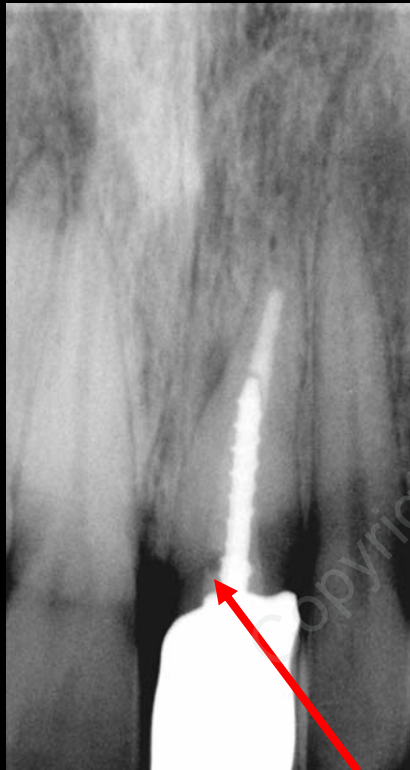
Guided Bone Regeneration/Socket Preservation

**Preserving the tooth alveolus/socket
following extraction. Single anterior tooth.
Uncomplicated.**

Drs. Alan Rosenfeld and George Mandelaris
Diplomates, American Board of Periodontology

Socket preservation

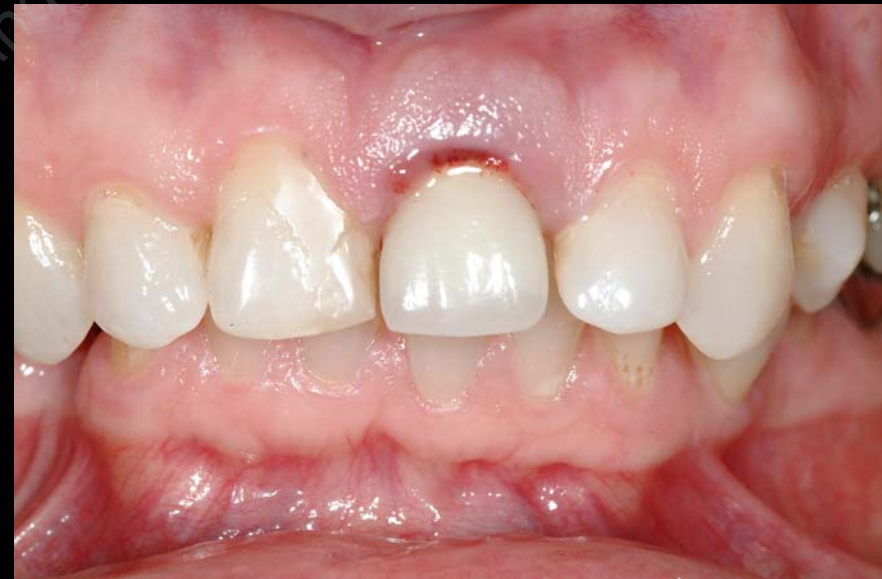Case Presentation



Initial X-ray: Infected #9 (red arrow)

Prognosis = Hopeless

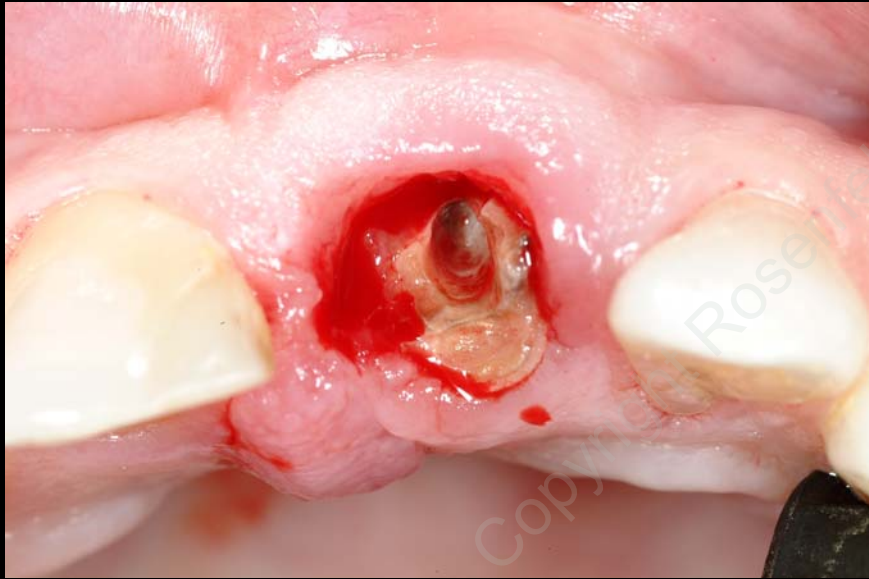Treatment is extraction + socket bone graft
to allow for a future dental implant



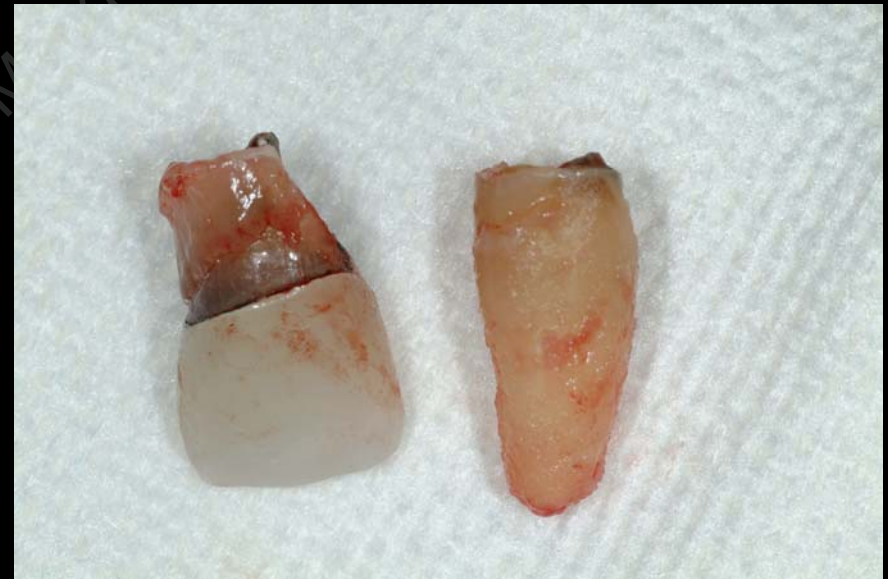Clinical photo shows the infected
tooth #9.

A fracture is noted which is non
restorable

Socket Preservation Bone Graft

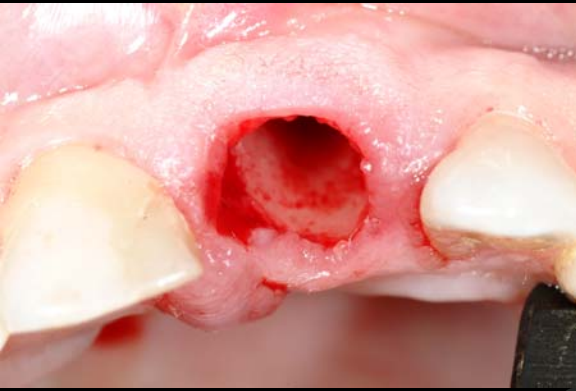

Horizontal fracture associated with tooth #9. This tooth can not be saved.

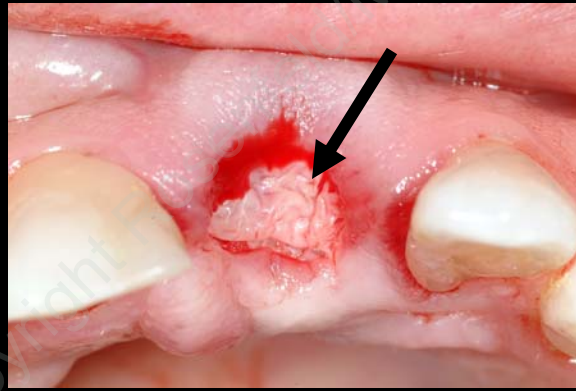


Tooth #9 is extracted in an atraumatic fashion. The fracture line is clearly visible in the photo above.

Socket Preservation Bone Grafting

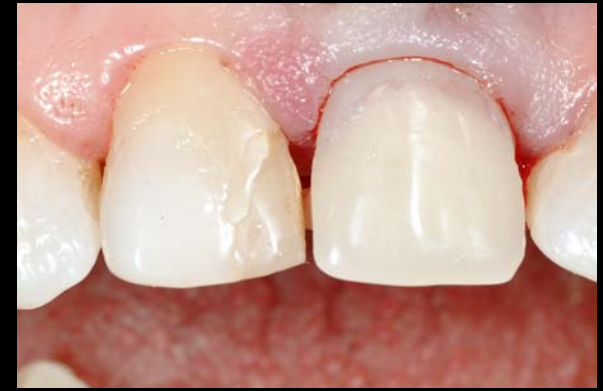

Following extraction of the fractured tooth, the tooth socket is carefully evaluated to confirm that all bone walls/dimensions are intact and that the infection is completely resolved.



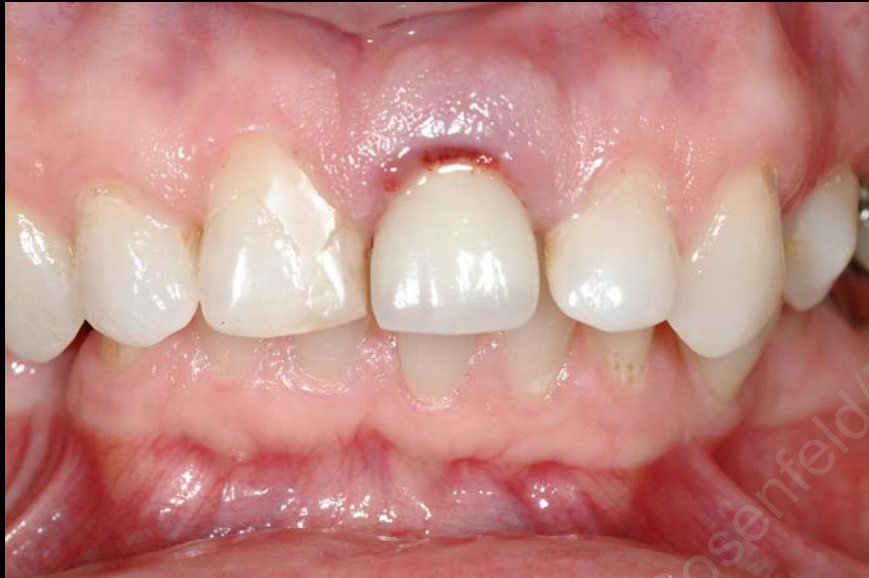A human donor allograft is placed into the tooth socket (see x-ray) & covered with a resorbable collagen membrane (arrow) for purposes of maintaining tooth socket dimensions & to prevent a normal, but dramatic bone loss pattern that will otherwise naturally occur within 3 months after tooth extraction.

This procedure will optimize the potential for uneventful implant placement in 4-6 months.

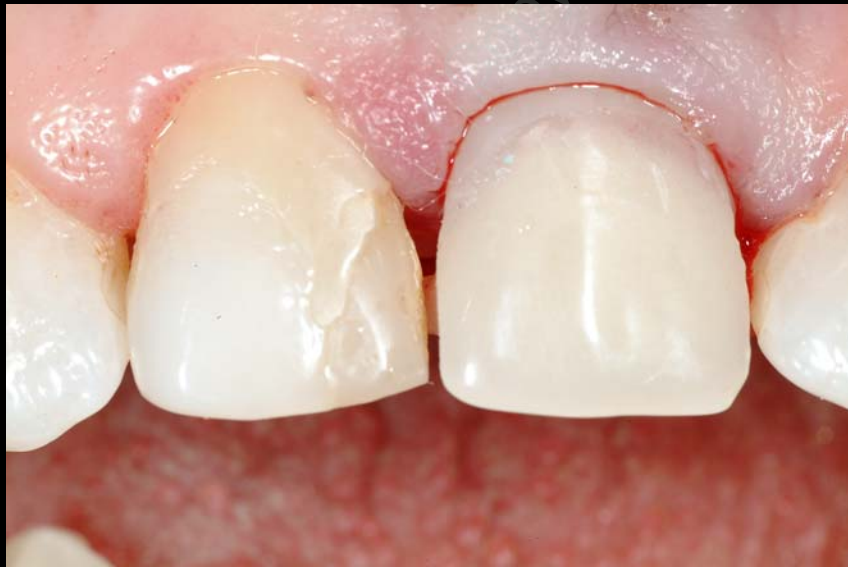
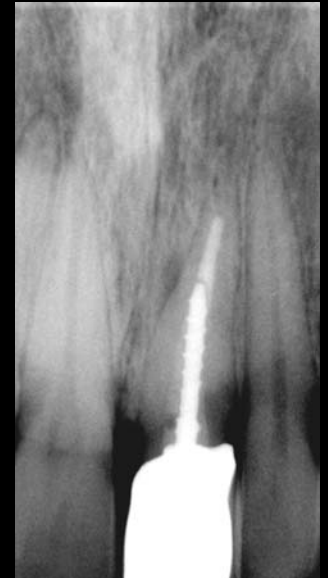
An interim (removable in this case) replacement tooth is immediately delivered to the patient at the surgery. This is performed to preserve the soft tissue (gum) architecture, maximizing the esthetic outcome.

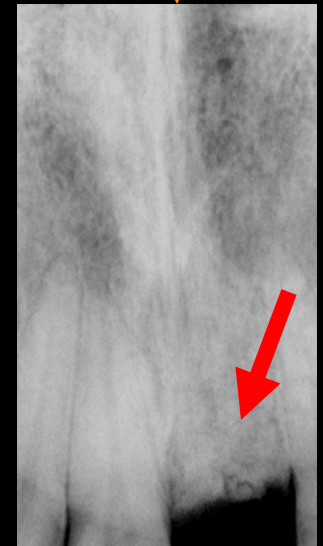
Socket Preservation Bone Grafting



BEFORE



AFTER



The x-ray shows the bone graft in the tooth socket (red arrow)