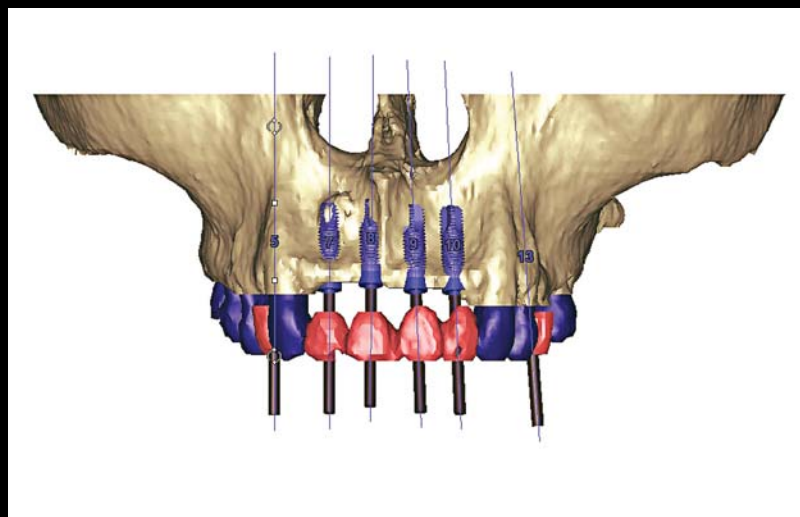


THE EXPANDING INFLUENCE OF COMPUTED TOMOGRAPHY AND THE APPLICATION OF COMPUTER-GUIDED IMPLANTOLOGY

George A. Mandelaris, DDS, MS*
Alan L. Rosenfeld, DDS†



Implant dentistry is changing. There are currently two types of computed tomography (CT) scanners—multi-slice and cone beam—available to the dental professional. Computed tomography allows for proactive planning among the entire implant team and with the patient, a concept referred to as “collaborative accountability.” In addition, CT surgical guidance that enhances accuracy and precision is available to ensure prosthetic outcomes. A logical and progressive approach is outlined that allows each clinician to assess how to embrace this paradigm shift in his or her clinical practice, and provide better and safer patient care.

Learning Objectives:

This article presents an approach that allows each clinician to consider the benefits of implementing computed tomography into his or her practice. Upon completion of this article, the reader should:

- Be aware of several steps that may be taken to implement CT scanning into a practice.
- Recognize the advantages and disadvantages of various types of CT scanning systems.

Key Words: implantology, Computed Tomography, scanning, precision

*Private practice, Park Ridge and Oakbrook Terrace, IL; Diplomate, American Board of Periodontology.

†Clinical Professor, Department of Graduate Periodontics, University of Illinois, School of Dentistry, Chicago, IL; private practice, Park Ridge and Oakbrook Terrace, IL; Diplomate, American Board of Periodontology.

**George A. Mandelaris, DDS, MS, Lutheran General Hospital, 1875 Dempster Street, Parkside Center, Suite 250, Park Ridge, IL 60068
Tel: 847-698-1180 • E-mail: GMandelari@aol.com**

A paradigm shift is occurring in implant dentistry. The advent and growing popularity of in-office, cone beam, computed tomography (CT) scanners, as well as independent imaging centers, is improving the diagnostic phase of patient care. Computed tomography implant treatment planning software and computer-generated surgical drilling guides have also transformed conventional methods of treatment to involve the patient and entire implant team. With the ability to plan and simulate surgery, as well as fabricate a provisional restoration prior to initiating treatment, the implant team can provide more consistent and predictable patient outcomes.¹⁻⁴

Recent CT technology has been focused on improving preoperative diagnoses, as well as the precision and accuracy associated with surgical execution of implant therapy to ensure prosthetic outcomes.⁵ Such applications are based on a prosthetically driven, presurgically developed plan.⁶ In this approach, information management has never been more crucial to the interdisciplinary team to ensure that anticipated

treatment outcomes are achieved. Fashionable technology and the excitement that it brings to clinical practice, however, should not usurp the evidenced-based decision-making process, nor the basic biological wound healing principles inherent to executing predictable delivery of treatment.⁷

Technological advances impart a responsibility on the treating clinician to assess and validate the transition from a "mental navigation" approach to one utilizing some level of sophisticated three-dimensional anatomical imaging (ie, CT scanning).^{8,9} In reality, each clinician must determine his or her own preferred situations in which CT technology should be applied to the clinical practice. This paper discusses the types of CT imaging available for diagnostics, the concept of collaborative accountability, and the utilization of CT surgical guidance to enhance accuracy and precision in implant therapy. The authors also present a logical and progressive approach on how to embrace this paradigm shift in clinical practice.

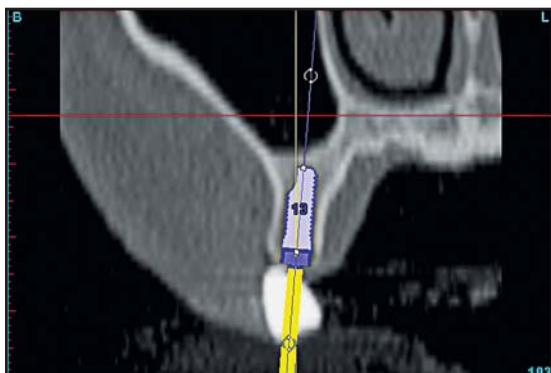


Figure 1. Cross-sectional view of a presurgically planned, prosthetically directed implant placement.

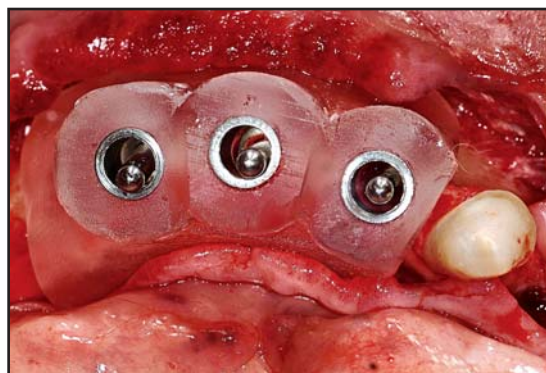


Figure 2. Bone-supported surgical guide (ie, SurgiGuide, Materialise Dental, Glen Burnie, MD) in place.

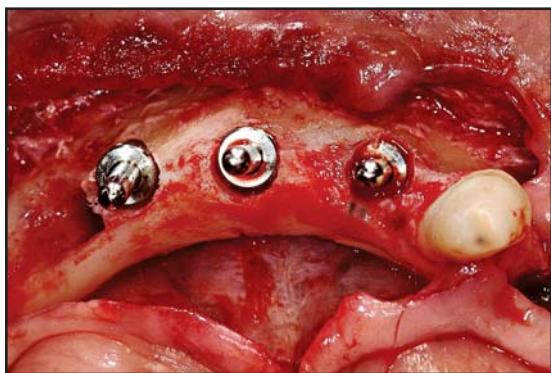

Figure 3. The surgical guide was removed during surgery.

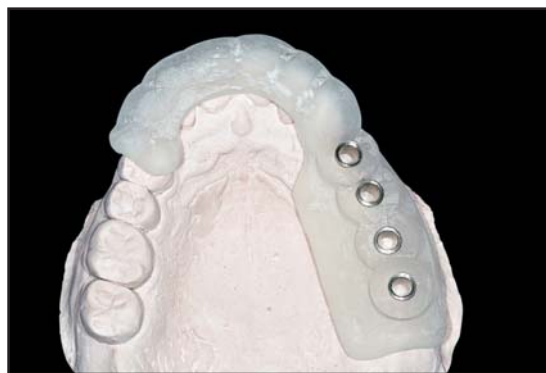

Figure 4. Tooth-supported surgical guide at the 3-mm level, fitted to an accurate stone model.

Table 1

Comparison of CT Imaging Systems		
Parameter	Type of CT Imaging System	
	Multi-slice CT (MSCT)	Cone Beam CT (CBCT)
Location	Hospital or imaging center. Site must adhere to Federal requirements.	Office of dental practitioner or imaging center. May or may not have an on-site radiation officer.
Position of patient	Supine	Sitting or standing
Image acquisition	Axial slices	Axial slices. Less spatial resolution in 3D.
Duration of imaging session	< 10 seconds	≤ 75 seconds
Radiation exposure	2.79 mGy to 16.14 mGy*	4.06 mGy to 5.92 mGy*
Radiation: effective dose	17.6 μSv to 656.9 μSv†	50.27 μSv†
Exposure to radiosensitive tissues	Minimal. Emits thin or collimated rays of ionizing radiation, allowing controlled imaging to tissue/structure.	Minimal. Does not utilize collimated rays and may expose tissues outside the area of interest to some radiation.
Number of times performed	For dental implant treatment planning, typically performed once.	For dental implant treatment planning, typically performed once.
Image quality/Resolution	<ul style="list-style-type: none"> • Highly discriminate grey scale • Excellent image quality (ie, ability to distinguish tissue types) 	<ul style="list-style-type: none"> • Less discrimination between grey scales • Good image quality
Film reader	Radiologist reads CT scan and assesses for focal abnormalities and pathology.	In-office practitioner assumes the risk or it is outsourced to a radiologist.
Compatibility with SimPlant®	Compatible	Compatible
Limitations with SimPlant®	None	Less accurate quantification of Hounsfield unit measurements.
Radiation quantified per patient exposure††	Yes	Can be quantified, but dependent on protocol of imaging site.

*As reported by Schulze et al, 2004, in a study that utilized head and neck phantoms.²⁰

†As reported by Mah et al, 2003, in a study that calculated the effective dose for a cone beam CT machine designed specifically for dental applications.¹³

††Estimated lifetime attributable risk of death resulting from one CT scan to the head is < 0.08%.²¹ Risk may be lower when limited only to mandible and maxilla.

CT Imaging in Dentistry

There are two main types of CT imaging currently available and applicable for implant diagnostics: conventional, multi-slice CT (MSCT) and cone beam CT (CBCT). As for any procedure requiring diagnostic imaging, each clinician and patient must make an informed decision based on the risk/benefit ratio as to whether MSCT, CBCT, or conventional film

dental radiography should be utilized for the given situation (Table 1).

Multi-slice CT scanners are found in hospitals or medical imaging centers, are large in size, and are not cost effective for dental practices. They generate a set of consecutive images on the axial or transverse plane, and these image slices can be reformatted for volumetric or three-dimensional representations of

body structures. The MSCT detector and tube assembly rotates in either a spiral or helical mode continuously around the patient (at several rotations per second) as the table moves into the gantry. X-rays emanate in a fan shape from the source, where there are multiple rows of detectors. These images have provided dentistry with the ability to more accurately and objectively diagnose patient conditions since Schwarz and Rothman first introduced the model in 1987.¹⁰⁻¹² The data set is traditionally read at the hospital or imaging center by a medical or dental radiologist.

Cone beam CT scanning has only recently become available for in-office use. These units are similar in size to a panorex machine and are less expensive than MSCT machines. Cone beam CT machines use a beam of x-rays emanating in a cone shape from the radiation source to a flat-panel detector and can capture the teeth and facial bones with a single rotation. The greatest benefit of CBCT is that the amount of radiation exposure is considerably less when compared to MSCT.¹³

The raw Digital Imaging Communications in Medicine (DICOM) data set acquired from either scanning modality is then formatted and processed to interactive software (eg, SimPlant, Materialise Dental, Glen Burnie, MD) that the clinician interprets and applies to the patient treatment planning process. There are, however, minor diagnostic and treatment planning limitations when CBCT data is interfaced with the software versus MSCT data.

Hounsfield units are a measure of x-ray attenuation for CT scans, and each pixel is assigned a value on a scale. The Hounsfield unit density is not as accurately quantified in CBCT because the radiation is not concentrated via a focused (ie, collimated) beam. Thus, the quality of three-dimensional reconstructions derived from CBCT may demonstrate less resolution compared to the resolution quality obtained from an MSCT scan. This may, to some degree, affect treatment planning, particularly if accurate presurgical evaluation of bone quality is critical to the decision-making process in treatment planning, choosing the surgical execution

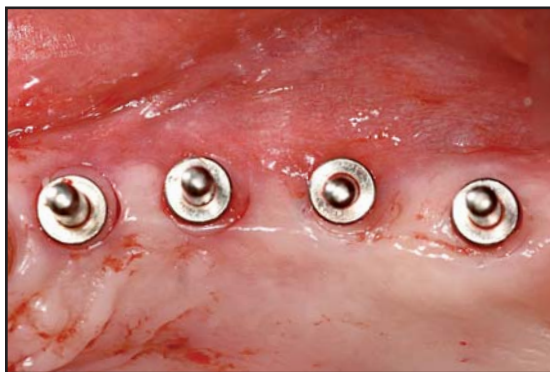

Figure 5. The 3-mm osteotomy site preparation was completed with a minimally invasive technique, and guide pins were positioned.

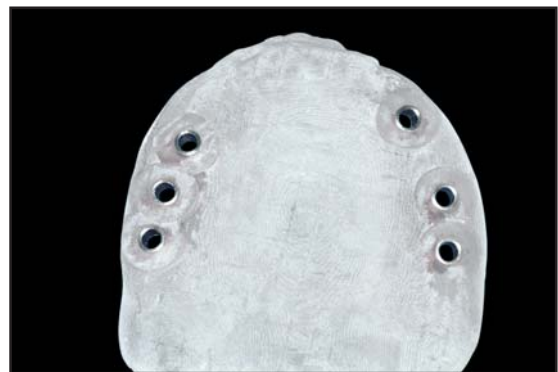


Figure 6. Mucosal-supported surgical guide (3-mm level) intended for a fully edentulous maxilla.

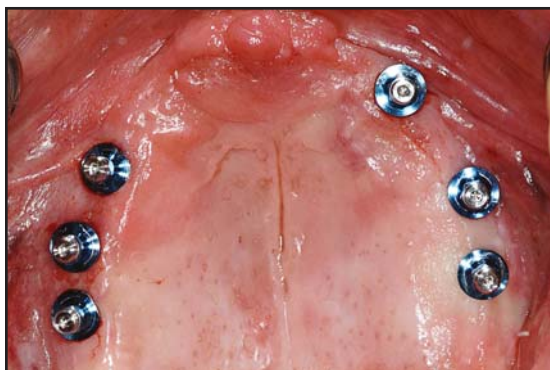

Figure 7. A partially-guided and flapless implant placement facilitated by a mucosal-supported surgical guide.

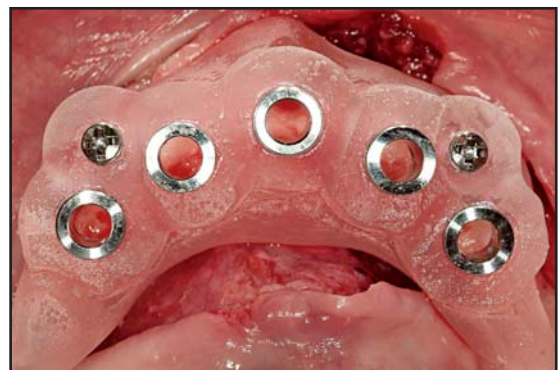


Figure 8. Occlusal view of bone-supported surgical guiding system (ie, SAFE System, Materialise Dental, Glen Burnie, MD) with stabilization screws in place.

Table 2

SurgiGuides—Risks and Benefits			
Type of Support	Type of Patient	Benefits	Risks
Bone-supported	Full or partially edentulous	<ul style="list-style-type: none"> • Visualization of surgical field • Stability of guide fit • Ease of drill placement in drill tubes • Elimination of drills used solely to perforate bone cortex • Reduction in overall surgical time 	<ul style="list-style-type: none"> • Requires significant bone exposure to properly seat guide
Tooth-supported	Partially edentulous	<ul style="list-style-type: none"> • Similar to bone-supported guide • Presence of natural dentition for support is required • Flapless surgery is an option 	<ul style="list-style-type: none"> • Existing dental prostheses may cause excessive imaging artifact, disabling guide construction
Mucosal-supported	Partially or completely edentulous	<ul style="list-style-type: none"> • Flapless surgery • Reduced pain and swelling • No sutures • Reduced surgical time 	<ul style="list-style-type: none"> • Major paradigm shift in performing procedures • Cannot visually confirm anatomy or surgical progress

of the case, or the informed consent process with the patient.¹⁴ Cone beam CT is, however, rapidly changing and an algorithm will likely be developed to address this minor limitation.

Increased imaging power requires greater diagnostic responsibility. It has been the authors' experience that significant incidental CT radiographic findings might have gone unnoticed had it not been for a co-interpretive effort of the CT data by a radiologist. At present, this collaborative effort appears to be more commonplace when MSCT scanners are used, rather than an in-office CBCT. Many cone beam centers, however, are outsourcing interpretations to satisfy this concern. In keeping with the ADA's policy on using diagnostic radiography, the ALARA (as low as reasonably achievable) principle should be followed.¹⁵

Implant Diagnostics

As previously discussed, scanning appliances allow the transfer of prosthetic information to the CT that

can be read through a proactive treatment planning program.^{2,3} Prosthetically driven, optimal final tooth position is a spatial tooth orientation that is related to the patient's underlying bony anatomy. Compatibility between the two for implant placement can be evaluated and treatment planning can ensue using the interactive software (Figure 1).⁶

Surgical Guidance

Traditional implant surgery involves the preparation of osteotomy sites with bone exposure. The CT scan may now be used as an informational management resource to best determine the type of guidance strategy the clinician wishes to use.

Computer-generated surgical osteotomy drill guides (eg, SurgiGuide, Materialise Dental, Glen Burnie, MD) are constructed through the process of stereolithography to control buccolingual and mesiodistal orientation (Figures 2 through 7).^{2,3,16} Vertical depth is a surgically derived calculation. Drill guide support can come from

bone, teeth, mucosa, or pre-existing dental implants. The precision and accuracy of osteotomy site preparations facilitated through computer-generated surgical osteotomy drill guides is superior to conventional methods (Table 2).^{8,17}

The next-generation surgical guide is equipped with an associated drilling system (ie, SAFE System, Materialise Dental, Glen Burnie, MD).¹⁸ This system is a completely guided approach to osteotomy site preparation and implant delivery. In some instances, the guide can be further stabilized by fixation screws (Figure 8). The drill design provides precise tolerance with respect to drilling tubes, thereby avoiding angulation error and heat generation. Specialized drills and drilling sleeves are utilized to control not only buccolingual and mesiodistal orientation, but also vertical depth. Although it is not implant-manufacturer specific, this particular approach is limited to use with standard diameter 4.1-mm external hex-top implants. Because of the growing interest and availability in utilizing CT scans and CT planning software, implant manufacturers are developing systems that will allow for a completely guided delivery approach with their implants. At present, there are three companies that have available CT guidance technology as a part of their armamentarium (ie, Navigator, BIOMET 3i, Palm Beach Gardens, FL; Facilitate, AstraTech Inc, Waltham, MA; NobelGuide, Nobel Biocare, Yorba Linda, CA). Other implant manufacturers will likely follow suit. These available systems all have inherent differences. The information derived from the CT scan allows the fabrication of a master cast using the CT surgical guide with implant analogs that matches what was planned in the software (Figures 9 through 11). The aesthetic, functional, laboratory processed provisional restoration can be prefabricated on the master cast for immediate seating at the time of implant placement with minimal chairside adjustment (Figures 12 and 13).

Collaborative Accountability

The ability to incorporate the prosthetic outcome into a CT data set marks a collaborative breakthrough between the implant surgeon and restorative dentist. This is the fundamental basis for a paradigm shift in implant dentistry that we refer to as "collaborative accountability." This concept allows the presurgical roles and responsibilities of the implant team to be determined.¹ There are five points to collaborative accountability:

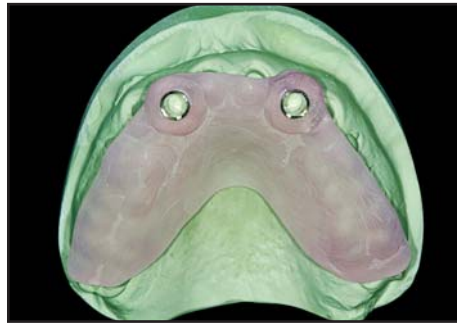

Figure 9. Diagnostic study model with tooth-supported surgical guide in position. Patient was congenitally missing teeth #7(12) and #10(22).

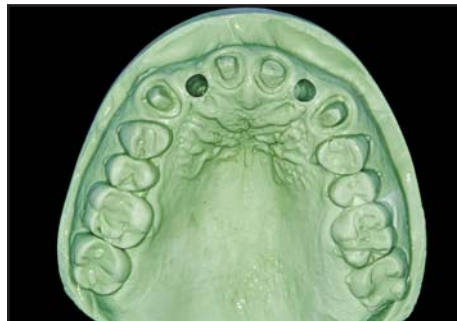

Figure 10. Preoperative diagnostic stone model with presurgically prepared osteotomy sites at the planned implant positions.

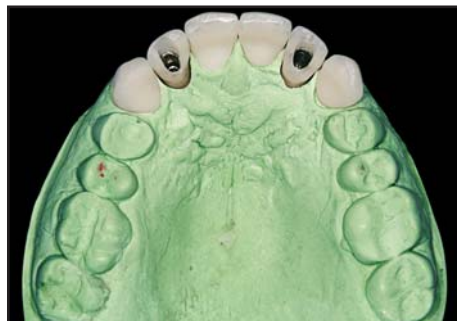

Figure 11. The maxillary model was articulated with a mandibular cast to create provisionals, which would be delivered at the time of surgery (courtesy of Dr. Dan Nykaza, Evanston, IL).

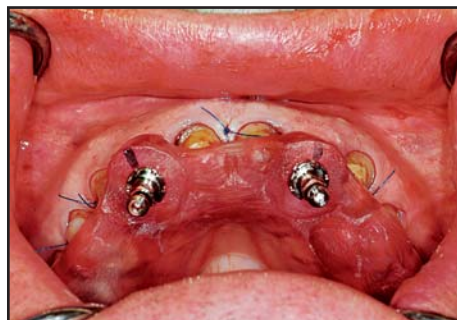

Figure 12. Minimally invasive and totally guided implant placement into preplanned prosthetically directed positions.

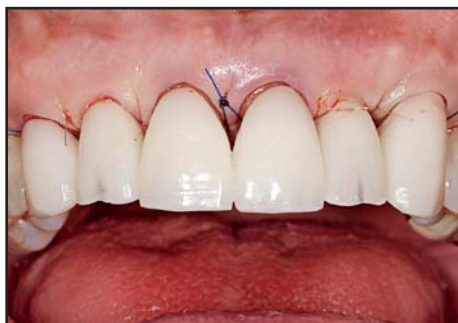

Figure 13. The provisionals for teeth #6(13) through #11(23). Teeth #7 and #10 were implant-retained.

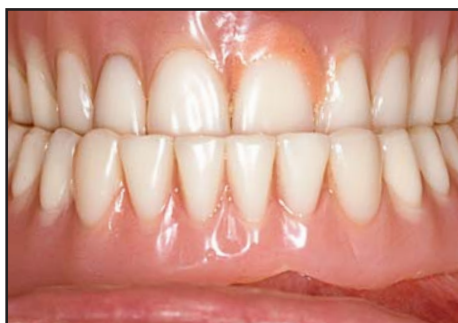

Figure 14. Initial intermaxillary denture position of patient.

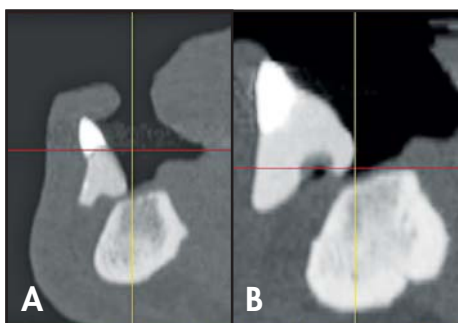


Figure 15A. Initial CT scan of the mandible with a third-generation scanning appliance in place. **15B.** Second CT scan showed that the incisal edge correctly bisected the vestibular fornix.

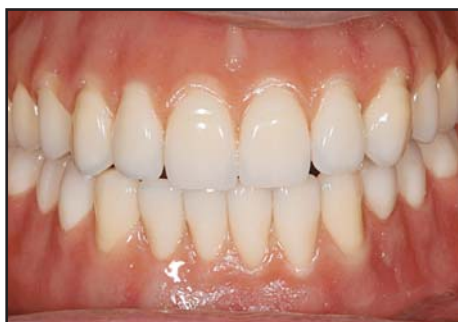

Figure 16. Diagnostic denture setup to establish proper prosthetic relationship from which surgical planning could begin.

- Prosthetic outcome determines surgical performance requirements the implant surgeon must follow. It also defines treatment limitations and costs preoperatively;
- Preoperative, not intra-operative planning, drives the treatment;
- Stereolithographic medical modeling reduces the surgical “talent gap” (ie, the placement of dental implants no longer relies on traditional “mental navigation” but rather on precise computer-guided implant positioning that is planned presurgically);
- The restorative dentist assumes a leadership role in interdisciplinary collaboration by setting the treatment performance standards for those participating in patient care; and
- The nature of the collaborative process is focused on the patient’s outcome.

Case Presentation

A 65-year-old, systemically healthy male presented for implant replacement therapy in the mandible. He had been completely edentulous for over 20 years, and his existing dentures were ill fitting (Figures 14 and 15). A duplicate of his pre-existing denture was transformed into a third-generation, barium gradient differential scanning appliance. Recognizing this prosthetic inaccuracy prior to the surgical event, but following the CT imaging, a diagnostic denture setup was completed and new dentures were fabricated that were aesthetically, phonetically, and functionally accurate (Figure 16). From this new denture position, a second third-generation, differential barium gradient scanning appliance was created for proper three-dimensional imaging and computer-guided implant treatment planning (Figure 15B). A flapless and completely guided surgical approach was undertaken (Figures 17 and 18). Immediate loading was also performed with the patient’s immediate load prosthesis fabricated presurgically using stereolithographically generated mucosal medical modeling (Figures 19 and 20). This case emphasized the importance of accurate prosthetic information in the scanning appliance to ensure proper surgical planning and execution. Surgery planned from a scanning appliance that did not accurately reflect the proper prosthetic outcome would have led to precise implant placement in locations that would not have supported the desired outcome.

Getting in the Game

With the rapid expansion of technology in dentistry, specifically with CT implant diagnostics and related surgical application, one must ask: "How do I best get into the game?" There are four logical and progressive strategies that the authors recommend in embracing CT technology as a part of practice. The first strategy is to do nothing other than utilize CT scans to enhance treatment planning. Computed tomography scans offer superior images over traditional radiographs and, when combined with interactive three-dimensional software, can provide accurate and predictable treatment planning. Implant cases may be performed using the traditional approach (ie, a conventional surgical template) with CT scans providing significantly improved diagnostic and treatment planning data, thus better preparing the surgeon, restorative dentist, and patient.

The second strategy involves the use of a bone-supported surgical drilling guide (eg, SurgiGuide, Materialise Dental, Glen Burnie, MD). This beginning step into guided surgery allows the surgeon to visualize, perform, and verify the progress of the procedure. The surgeon can visually confirm surgical progress and, if necessary, discontinue the use of the guide if treatment is inaccurate. A conventional template is recommended during surgery to enable prosthetic verification when ever possible.

The third strategy is the use of a tooth-supported drilling guide. This guide may or may not be removed. The clinician may or may not choose to visualize the surgical field to assess any deviation from the anticipated outcome. This could allow a minimally invasive approach to be taken, if desired. In the event that the guide is removable, the use of a conventional surgical template is recommended to verify that the osteotomy positioning is correct in relation to optimal final tooth position. Model surgery may also be performed prior to treatment to confirm accuracy with the expected outcome (Figures 6 and 7).

In the second and third strategies, partial guidance may be expanded to include a totally guided approach to osteotomy site preparation and implant delivery. Since the totally guided approach is less recoverable and, therefore, incurs the greatest risk, attempting surgery with complete guidance should not be undertaken until experience in computer-guided implant planning and surgery has been acquired.

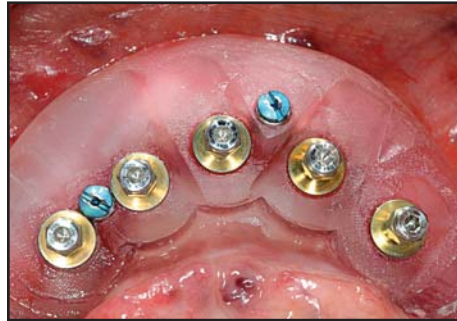


Figure 17. Mucosal-supported surgical guide in position. The implants were delivered to the desired three-dimensional position.

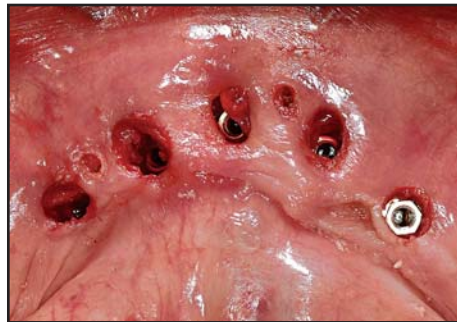

Figure 18. Occlusal view following removal of the surgical guide and flapless implant placement. Immediate loading would then follow.

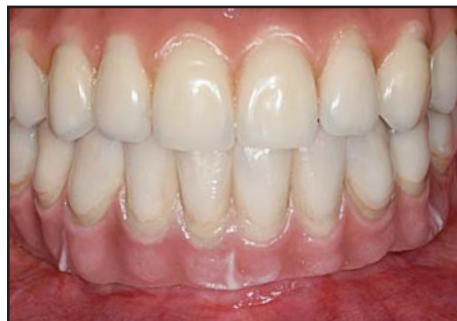

Figure 19. Facial view of the final prosthetic outcome (courtesy of Dr. Brian Vence, West Dundee, IL).

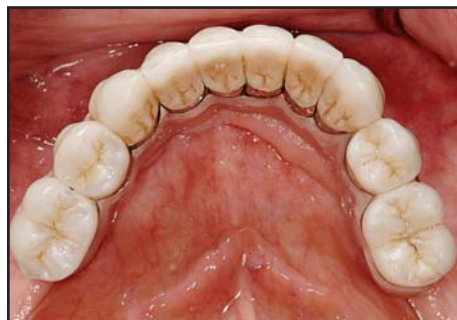

Figure 20. Occlusal view of the final prosthetic outcome (courtesy of Dr. Brian Vence, West Dundee, IL).

The fourth strategy is using a guide that is placed directly on the edentulous tissues. These guides may be fixed on position and implants placed in a flapless manner. A partially or completely guided approach may be taken. This is a true minimally invasive method of performing implant surgery, and offers the clinical benefit of reduced swelling and pain. A blinded approach, however, is associated with the highest risk and demands the most precision in the prosthetic work up, scanning appliance fabrication, imaging quality, treatment planning, and surgical execution. This paradigm shift requires the greatest leap of faith from conventional implant surgery. It should, therefore, be utilized by the most experienced clinicians.

Conclusion

Surgical tourism no longer has to be the point of discovery. Clinicians have a professional opportunity to provide better and safer patient care by using CT imaging technology to ensure an accurate diagnosis and treatment strategy that addresses the needs and concerns of both the patient and the implant team. While not all implant cases require CT scans for successful outcomes, complex cases involving implant therapy will benefit from cross-sectional imaging information, and it is agreed that CT scans provide the most accurate assessment of a patient's anatomy.¹⁹ Perhaps the most under-appreciated aspect of CT imaging in the diagnostic treatment planning process is the ability for the implant team to consult between treatment disciplines—and with the patient—in an atmosphere of complete disclosure prior to the procedure.

Acknowledgements

The authors mention their gratitude to Ms. Jackie Kalbach, Richard Mecall, DDS, and Laura Lomasney, MD, for their assistance in the preparation of this manuscript. The preparation of this article was funded in part by Materialise Dental. The authors are consultants for, but declare no financial interest in Materialise Dental.

References

- Rosenfeld AL, Mandelarlis GA, Tardieu PB. Prosthetically directed implant placement using computer software to ensure precise placement and predictable prosthetic outcomes. Part 1: Diagnostics, imaging, and collaborative accountability. *Int J Periodont Rest Dent* 2006;26(3):215-221.
- Rosenfeld AL, Mandelarlis GA, Tardieu PB. Prosthetically directed implant placement using computer software to ensure precise placement and predictable prosthetic outcomes. Part 2: Rapid-prototype medical modeling and stereolithographic drilling guides requiring bone exposure. *Int J Periodont Rest Dent* 2006;26(4):347-353.
- Rosenfeld AL, Mandelarlis GA, Tardieu PB. Prosthetically directed implant placement using computer software to ensure precise placement and predictable prosthetic outcomes. Part 3: Stereolithographic drilling guides that do not require bone exposure and the immediate delivery of teeth. *Int J Periodont Rest Dent* 2006;26(5):493-499.
- Ganz SD. Use of stereolithographic models as diagnostic and restorative aids for predictable immediate loading of implants. *Pract Proced Aesthet Dent* 2003;15(10):763-771.
- Ganz SD. CT-derived model-based surgery for immediate loading of maxillary anterior implants. *Pract Proced Aesthet Dent* 2007;19(5):311-318.
- Mecall RA, Rosenfeld AL. The influence of residual ridge resorption patterns on implant fixture placement and tooth position. Part 2. Presurgical determination of prosthesis type and design. *Int J Periodont Rest Dent* 1992;12(1):32-51.
- Malmquist JP. Complications: Why? *Int J Periodont Rest Dent* 2007;27(1):5.
- Sarment DP, Sukovic P, Clinthorne N. Accuracy of implant placement with a stereolithographic surgical guide. *Int J Oral Maxillofac Impl* 2003;18(4):571-577.
- Vrielinck L, Politis C, Schepers S, et al. Image-based planning and clinical validation of zygoma and pterygoid implant placement in patients with severe bone atrophy using customized drill guides. Preliminary results from a prospective clinical follow-up study. *Int J Oral Maxillofac Surg* 2003;32(1):7-14.
- Schwarz MS, Rothman SL, Rhodes ML, Chafetz N. Computerized tomography. Part I. Preoperative assessment of the mandible for endosseous implant surgery. *Int J Oral Maxillofac Impl* 1987;2(3):137-142.
- Schlueter B, Kim KB, Oliver D, Sortiropoulos G. Cone beam computed tomography 3D reconstruction of the mandibular condyle. *Angle Orthod* 2008;78(5):880-888.
- Schwarz MS, Rothman SL, Rhodes ML, Chafetz N. Computerized tomography. Part II. Preoperative assessment of the maxilla for endosseous implant surgery. *Int J Oral Maxillofac Impl* 1987;2(3):143-148.
- Mah JK, Danforth RA, Bumann A, Hatcher D. Radiation absorbed in maxillofacial imaging with a new dental computed tomography device. *Oral Surg Oral Med Oral Pathol Oral Radiol Endod* 2003;96:508-513.
- Misch CE. Bone density—A key determinant for clinical success. In: Misch CE (ed). *Contemporary Implant Dentistry*. 2nd edition. St Louis, MO: Mosby; 1999:1009-1119.
- ADA Council on Scientific Affairs. The use of dental radiographs. Update and recommendations. *J Am Dent Assoc* 2006;137:1304-1312.
- Ganz SD. Presurgical planning with CT-derived fabrication of surgical guides. *J Oral Maxillofac Surg* 2005;63(9):59-71.
- Van Assche N, van Steenberghe D, Guerrero ME, et al. Accuracy of implant placement based on presurgical planning of three-dimensional cone-beam images: A pilot study. *J Clin Periodontol* 2007;34(9):816-821.
- Tardieu P, Vrielinck L. Implantologie assistée par ordinateur: Le programme SimPlant SurgiCase et le SAFE System. Cas clinique: Mise en charge immédiate d'un bridge mandibulaire avec des implants transmuqueux. *Implant* 2003;32:7-14.
- Sonick M, Abrahams J, Faiella R. A comparison of the accuracy of periapical, panoramic, and computerized tomographic radiographs in locating the mandibular canal. *Int J Oral Maxillofac Impl* 1994;9(4):455-460.
- Schulze D, Heiland M, Thurmman H, Adam G. Radiation exposure during midfacial imaging using four- and 16-slice computed tomography, cone beam computed tomography systems and conventional radiography. *Dentomaxillofac Radiol* 2004;33(2):83-86.
- Brenner DJ, Hall EJ. Computed tomography—An increasing source of radiation exposure. *N Engl J Med* 2007;357(22):2277-2284.

CONTINUING EDUCATION (CE) EXERCISE No. 10

To submit your CE Exercise answers, please use the answer sheet found within the CE Editorial Section of this issue and complete as follows: 1) Identify the article; 2) Place an X in the appropriate box for each question of each exercise; 3) Clip answer sheet from the page and mail it to the CE Department at Montage Media Corporation. For further instructions, please refer to the CE Editorial Section.

The 10 multiple-choice questions for this Continuing Education (CE) exercise are based on the article "The Expanding Influence of Computed Tomography and the Application of Computer-Guided Implantology," by George A. Mandelaris, DDS, MS, and Alan L. Rosenfeld, DDS. This article is on Pages 297-305.

1. Which of the following imaging modalities for implant diagnostics has the highest accuracy on all levels?

- a. MSCT.
- b. CBCT.
- c. Plain film.
- d. Panorex.

2. Which of the following is the primary advantage of CBCT scanners when compared to MSCT?

- a. Cost of the unit.
- b. Radiation dose.
- c. Size of the unit.
- d. Duration of imaging required.

3. Which of the following types of surgical implant guided support is generally not feasible?

- a. Bone-supported.
- b. Mucosal-supported.
- c. Tooth-supported.
- d. Tooth-bone-supported.

4. The purpose of an accurate scanning appliance is to:

- a. Help establish the prosthetic outcome prior to surgery.
- b. Allow the surgeon to accurately relate a patient's anatomy to final tooth position.
- c. Assist in the informed consent process about the requirements necessary for the team to achieve the patient's desired goal.
- d. All of the above.

5. Which of the following is the best place to begin the paradigm shift into computer-guided implantology?

- a. Immediate load prosthesis cases where surgical guidance will be used.
- b. Single-tooth immediate provisional implant cases that require the use of a surgical guide.
- c. Utilization of CT scans and guided implant placement software for improved preoperative decision making.
- d. Implant surgery cases that involve more than one fixture.

6. Multi-slice CT scanning systems provide:

- a. Lengthy imaging session durations.
- b. Thin or collimated rays of ionizing radiation that allow controlled imaging to tissue structure.
- c. No usage of collimated rays and may expose the tissues outside of the area of interest to minimal radiation.
- d. None of the above.

7. Which is the greatest limitation of CBCT scanners when compared to MSCT?

- a. Time involved in imaging a patient.
- b. Maintenance and associated cost for unit upkeep.
- c. Inaccurate Hounsfield measurements.
- d. Radiation exposure required to image a patient.

8. Which of the following is a drawback to utilizing computer-guided implantology?

- a. Reduced surgical time.
- b. More accurate implant placement.
- c. Increased time demanded during diagnostic planning.
- d. Enables a more enhanced informed consent process.

9. What is collaborative accountability?

- a. A philosophical mantra that embraces the team concept and is centered around the patient's outcome.
- b. A paradigm shift in leadership roles for implant dentistry whereby the restorative dentist drives treatment by setting performance standards that the team must follow.
- c. Preoperatively based treatment planning using 3D diagnostic information to make treatment decisions, enhance the informed consent, and provide more accurate prosthetically directed implant placement.
- d. All of the above.

10. Image acquisition using cone beam technology is generally less spatial because it provides:

- a. Cross-sectional slices.
- b. Panoramic slices.
- c. Axial slices.
- d. None of above.