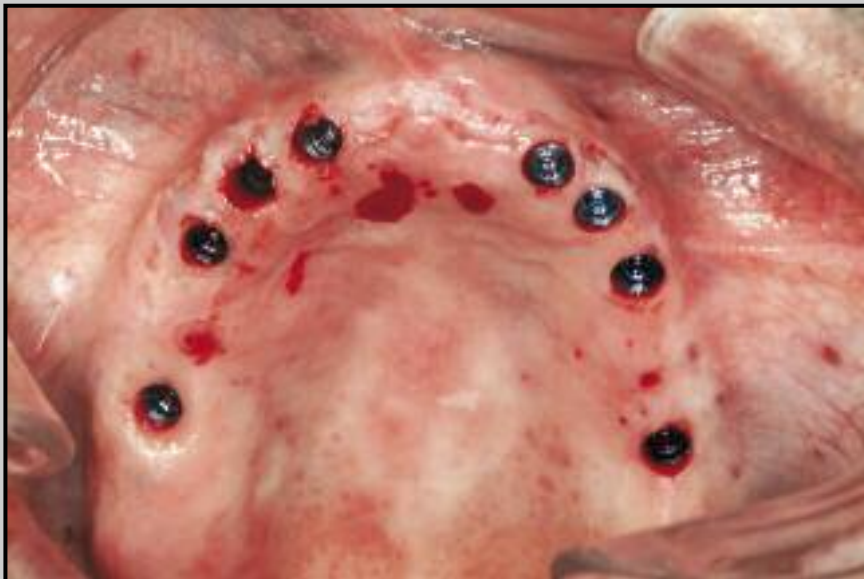
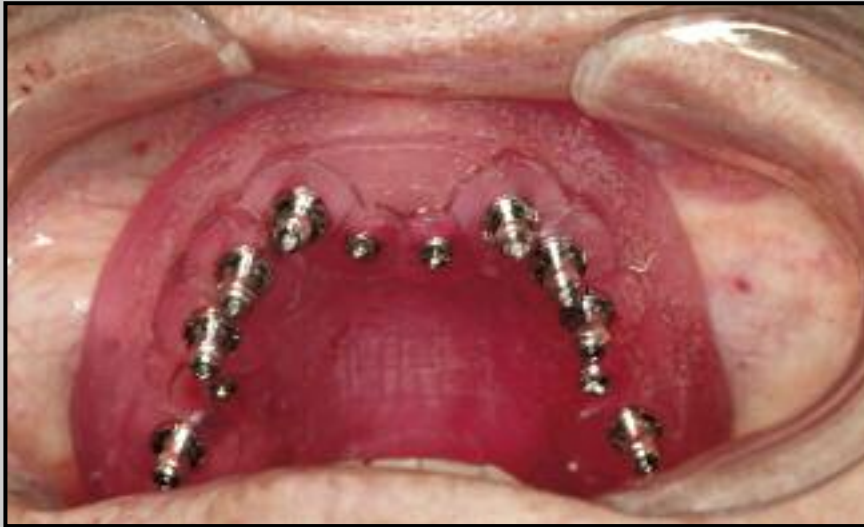
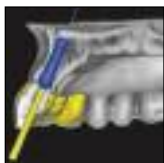

Computer-Guided Implant Dentistry for Precise Implant Placement: Combining Specialized Stereolithographically Generated Drilling Guides and Surgical Implant Instrumentation



George A. Mandelaris, DDS, MS*

Alan L. Rosenfeld, DDS**

Samantha D. King, DMD***

Marc L. Nevins, DMD, MMSc****

The application of computed tomography (CT) and the use of computer software for dental implant therapy have significantly increased during the last several years. Dental implant positioning can be either "partially guided," where only osteotomy sites are prepared using sequential, removable surgical drilling guides (generated using computer software and through the process of stereolithography), or "totally guided," whereby one guide is used for osteotomy site preparation as well as implant delivery. Recently, the guided delivery of manufacturer-specific internal-connection implants has become available. Individualized protocols and specific instrumentation are employed under this approach to CT-based implant surgery. The purpose of this article is to expand on previous publications related to the use of prosthetically directed implant placement using computer software to ensure precise placement and predictable prosthetic outcomes. Three case reports are presented where precision-guided CT-based surgery was employed and the immediate delivery of a dental prosthesis was facilitated. (Int J Periodontics Restorative Dent 2010;30:275–281.)

*Private Practice, Park Ridge and Oakbrook Terrace, Illinois.

**Private Practice, Park Ridge and Oakbrook Terrace, Illinois; Clinical Professor, Department of Graduate Periodontics, University of Illinois, College of Dentistry, Chicago, Illinois.

***Private Practice, Boston, Massachusetts.

****Private Practice, Boston, Massachusetts; Clinical Assistant Professor, Department of Periodontics, Harvard School of Dental Medicine, Boston, Massachusetts.

Correspondence to: Dr George A. Mandelaris, 1875 Dempster Street, Suite 250, Parkside Center, Lutheran General Hospital, Park Ridge, IL 60068; email: GMandelari@aol.com.

The advent and growing popularity of in-office cone beam computed tomography (CT) scanners as well as the availability of imaging centers has improved diagnostics for dentistry as a whole. With its growing awareness and popularity in three-dimensional (3D) technology, implant companies are now incorporating CT-based guided implant dentistry into their armamentariums for clinicians.¹ The role of computer-guided implant dentistry is expanding to offer the delivery of specific implants into presurgically determined prosthetic positions in all three planes of space: buccolingual, mesiodistal, and apico-coronal. In addition, the opportunity for an immediately loaded prosthesis or an immediate–nonocclusal load prosthesis can be facilitated by such opportunities and protocols.^{2–5}

The purpose of this article is to expand on previous publications related to computer-guided implant dentistry by relating the concept of precise, totally guided CT-based surgery for internal-connection implants. Three case reports are presented to demonstrate the applicability and versatility of precision-guided CT-based surgery in clinical practice.

CT surgical guidance

Prosthetically directed implant placement using computer software to ensure precise placement and predictable prosthetic outcomes using rapid-prototype medical modeling and stereolithographic drilling guides has been described in previous publications.⁶⁻⁸ The initial phase of this paradigm shift from a traditional approach of implant placement to one that is "computer-guided" included either drilling guides that were used solely for osteotomy site preparation (ie, partially guided; SurgiGuides, Materialise Dental) or involved the use of a single guide for both osteotomy site preparation and implant delivery (ie, totally guided; SAFE SurgiGuide system, Materialise Dental).

The partially guided technique with SurgiGuides allows for a controlled osteotomy site preparation in two planes of space: buccolingual and mesiodistal. In this approach, multiple sequential drilling guides are used for precise osteotomy site preparation. Vertical depth is a surgical calculation and is not controlled. The drilling guides are removed for countersinking (if necessary) and implant placement is performed using the traditional nonguided approach. Implant placement is then performed manually at the "computer-guided" osteotomy sites.

The SAFE SurgiGuide system is the original totally guided implant system, allowing for controlled osteotomy site preparation and implant placement in three dimensions.⁹ Similar technology has been adapted for use in other commercial systems.¹ SurgiGuides and the SAFE SurgiGuide system are ver-

satile in that they can be used on either bone, tooth, or mucosal supporting surfaces.⁶⁻⁸ The proof of principle established in the SAFE SurgiGuide system merely required mechanical modification to facilitate the delivery of internal-connection implants.

Totally guided precision CT-based surgery using the SAFE SurgiGuide system concept allows versatility in the supporting surface (bone, tooth, tooth-mucosa, mucosa) but uses a single guide for osteotomy site preparation and implant placement. Specific cylinders are embedded within the acrylic resin guide to accommodate drill handles or similar components that intimately engage the cylinders. Osteotomy site-specific drills are then used that have vertical stops to control apicocoronal osteotomy site preparation. Countersinking is also controlled and tolerances are highly precise. Drill size and drill handle application are chosen depending upon the specific needs of the patient and the individualized CT plan. Implant placement is performed using specific delivery mounts and to a controlled buccolingual, mesiodistal, and apicocoronal depth, which is set by the computerized 3D plan.

Fixation of these guides can be used to prevent displacement. The system presented in this report includes technology to control hex orientation. This is possible through unique alignment grooves that are positioned within the guiding cylinder and at the top of the delivery mounts. All three patients in this report were treated using the Navigator SurgiGuide System (Biomet 3i and Materialise Dental).

Patient 1

A 53-year-old man presented with generalized advanced chronic periodontitis and gross dental caries associated with his mandibular dentition. A strategy to transition the patient's natural dentition to an implant-supported prosthesis was developed. As part of the interdisciplinary work-up, mounted maxillomandibular casts were obtained and a new maxillary denture was fabricated. The existing mandibular teeth were determined to be in nearly optimal positions compared to the plan for a fixed implant-supported metal-ceramic prosthesis. Because of this unique situation, no scanning appliance was needed and his existing teeth were used as the optimal final tooth positions. The patient was referred for CT scan imaging of the mandible with the appropriate masks, which were transferred into a dental implant-planning computer software program (SimPlant Planner, Materialise Dental) for diagnostic and treatment planning purposes (Fig 1a). Masks are an important part of the processing procedure since different object densities can be manipulated to create specialized viewing opportunities that are critical to the treatment planning process (Fig 1a).⁵ Prior to surgery and during the planning phase, control of the patient's periodontitis and local inflammation was pursued via scaling and root planing periodontal therapy.

Following intravenous conscious sedation and delivery of local anesthesia, atraumatic extraction of the remaining mandibular natural dentition was performed. A full-thickness flap reflection was performed and all

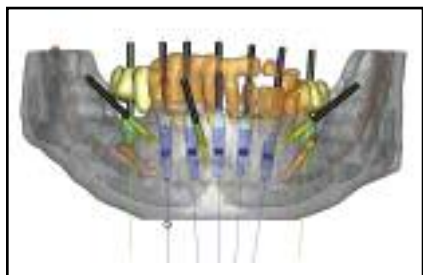
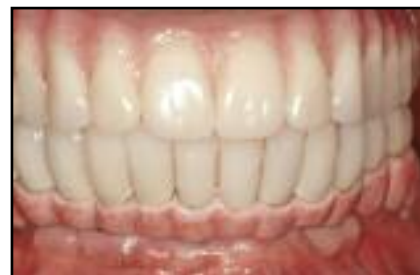

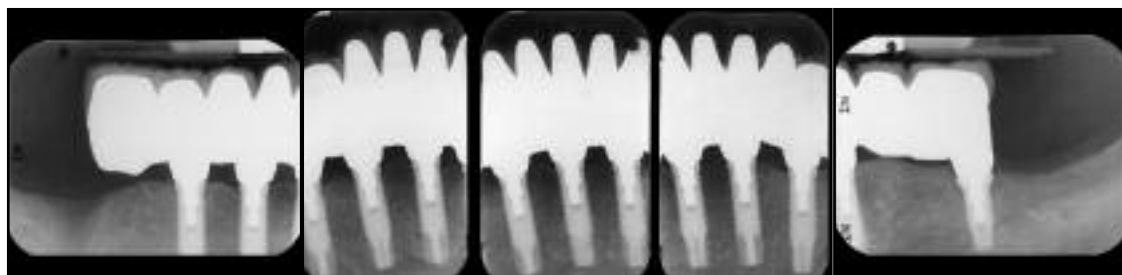Fig 1a CT scan and 3D implant treatment planning of a hopeless mandibular dentition. Implants (blue) and stabilization screws (yellow) were planned. Masks of the mandible, remaining natural teeth, virtual mandibular right second premolar and first molar and left first molar, and inferior alveolar nerves are present.



Fig 1b Bone-supported Navigator SurgiGuide seated and fixated using pre-planned stabilization screws and totally guided implant placement in the anterior mandible.



Figs 1c and 1d (above) Final prosthetic outcome and (below) final radiographs of patient 1 (Courtesy of Dr Paul Imhof, Des Plaines, Illinois).



sockets were degranulated. Several millimeters of unusable alveolar bone were then eliminated via a stereolithographically generated bone reduction guide. Following a precise and guided osteoplasty, the bone-supported Navigator SurgiGuide was then seated to the underlying bone surface and verified for stability and accurate positioning. Additional stability was ensured by the placement of three stabilization screws at preplanned sites (Fig 1a). Totally guided osteotomy site preparation and implant delivery were then pursued according to the individualized protocol for the patient

(Fig 1b). Following the delivery of seven endosseous Nanotite Certain (Biomet 3i) implants at preplanned sites, the surgical guide was removed and implant stability was verified. A presurgically fabricated immediate-load prosthesis was seated on the five interforaminal implants. Following 4 months of healing, osseointegration was confirmed, at which time one unloaded implant (mandibular right first molar, single-stage surgery) was found unintegrated. The prosthetic phase was completed with a fixed metal-ceramic prosthesis (Figs 1c and 1d).

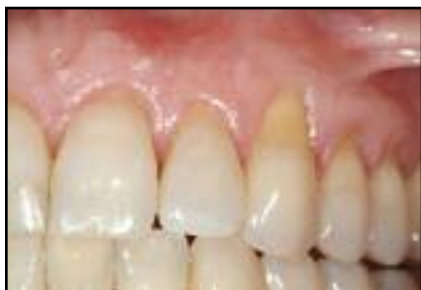

Fig 2a (left) Preoperative presentation of a hopeless maxillary lateral incisor.

Fig 2b (right) 2D cross-sectional view imposed on a 3D rendering (ie, "clip art") for the maxillary left lateral incisor.

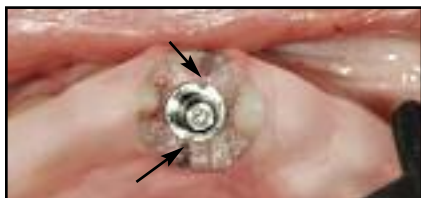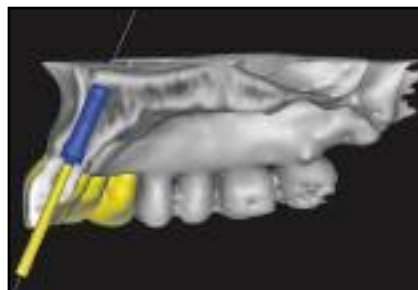

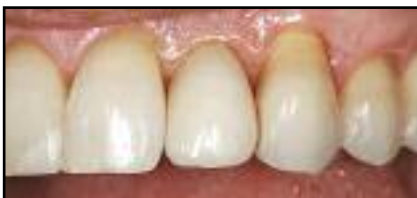
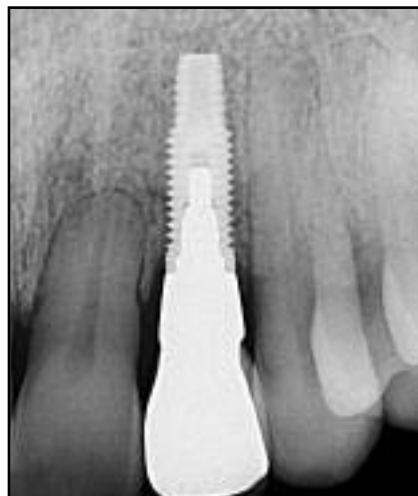Fig 2c Tooth-supported Navigator SurgiGuide in position. Flapless, totally guided implant placement was accomplished. Note the unique alignment grooves that are positioned within the guiding cylinder and at the top of the delivery mounts, which enable control of the hex orientation (arrows).



Figs 2d and 2e (above) Final prosthetic outcome and (right) final radiograph of the restored lateral incisor (Courtesy of Dr Joseph Silberman, Evanston, Illinois).



Patient 2

A 44-year-old woman presented with advanced root resorption at the maxillary left lateral incisor (Fig 2a). The consultation process included a treatment plan for an implant-supported restoration involving precision-based CT-guided implant surgery and immediate placement of a fixed provisional restoration (Fig 2b).

Diagnostic study casts were mounted. The maxillary stone cast was retrofitted at the maxillary left lateral incisor with an implant analog using the surgical guide and allowing for the fabrication of a laboratory provisional crown on an interim abutment. Under local

anesthesia, the maxillary lateral incisor was extracted, the tooth-supported Navigator SurgiGuide was seated, and stability was verified, allowing for precise, flapless implant placement under total guidance (Osseotite Certain, Biomet 3i) (Fig 2c). Following 3 months of uneventful healing, the final prosthetic phase was completed (Figs 2d and 2e). Connective tissue grafting was performed at the site of the maxillary left canine for partial root coverage and mucogingival augmentation at a separate surgery.

Patient 3

An 85-year-old woman presented with a failing maxillary fixed partial denture. After being transitioned to an interim maxillary complete denture and allowing 3 months of postextraction healing, the patient proceeded with evaluation for an immediate fixed provisional prosthesis implementing precision-based CT-guided surgery.

The appropriate esthetics, phonetics, occlusal stability, vertical dimension, and denture base fit were verified with the patient's denture. The denture was then duplicated for fabrication of a third-generation (Tardieu) scanning appliance (Fig 3a).⁵ The scanning

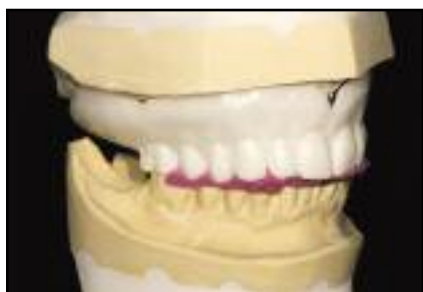

Fig 3a Mounted differential barium gradient scanning appliance in position with the bite registration (pink).

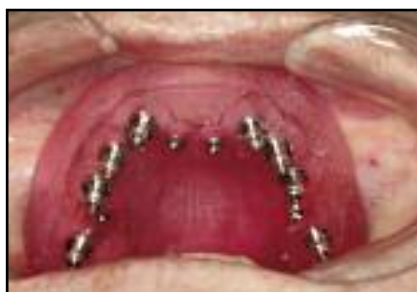

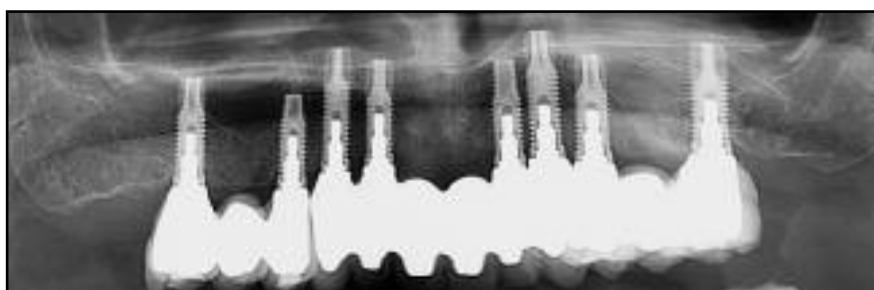
Fig 3b Totally guided, flapless osteotomy site preparation was completed and implant delivery accomplished via a mucosa-supported Navigator SurgiGuide.

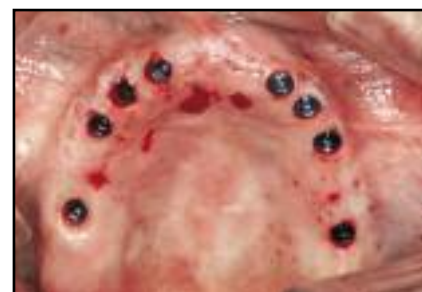
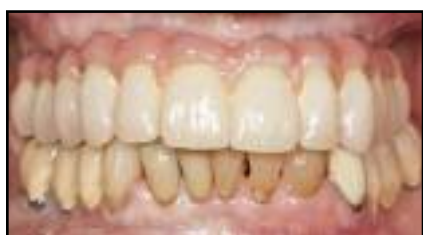
Fig 3c Totally guided, flapless implant placement was completed and the Navigator SurgiGuide was removed.



Figs 3d and 3e (left) Final prosthetic outcome and (right) final radiograph of patient 3.



appliance was stabilized during the imaging process via a radiolucent bite record. Computerized treatment planning was performed using SimPlant to determine the precise angulations and positions for eight implants in the maxillary arch. Four stabilization screws were planned and incorporated into the surgical guide for fixation during implant placement.

A mucosa-supported Navigator SurgiGuide was then used to create a working cast for fabrication of the provisional maxillary fixed partial denture by inserting implant analogs attached to specific laboratory delivery mounts into the guide using the Navigator prosthetic kit. A soft tissue masque

was syringed around the analogs and silicone lubricant placed on the remainder of the surgical guide before pouring in an accurate dental stone, which served as the working cast. The working cast was mounted on an articulator opposing the cast of the mandibular arch by placing the radiographic template on the working cast with the corresponding bite record. This bite record was then transferred to the surgical guide to create a surgical bite record. The fit of this surgical bite record and guide was confirmed clinically before surgery.

Implant surgery was performed under local anesthesia. Treatment was initiated by positioning the surgical

guide on the maxilla with the surgical bite record and then fixing it with four stabilization screws. The implant sites were then prepared via the Navigator SurgiGuide and its individualized protocol for the patient (Figs 3b and 3c). Following implant placement, eight custom and presurgically created abutments were delivered using a positioning jig and hand tightened into place. The fit and occlusion of the cross-arch provisional were verified as being accurate and consistent with what had been planned. The provisional was then cemented using temporary cement. At 6 months postsurgery, treatment began for the definitive metal-ceramic prosthesis (Figs 3d and 3e).

Discussion

CT-guided implant surgery is becoming a more common modality of implant therapy. This article demonstrates the versatility of CT-guided technology, specifically of the Navigator SurgiGuide system, which can facilitate the delivery of internal-connection dental implants and, when indicated, an immediate dental prosthesis.

Several authors have demonstrated that stereolithographically generated CT surgical drilling guides offer enhanced precision and accuracy when compared to the conventional nonguided approach to osteotomy site preparation.¹⁰⁻¹⁵ Most of these articles have shown implant positioning entry point (axial plane) deviations of 1 mm and angle deviations of around 5 degrees. The totally guided approach may further minimize these entry point and angle deviations because of the potential influence of operator positioning error when using more than one guide or placing implants manually. Inherent errors such as guide movement and the influence of bone density need to be considered on these deviations when comparing both approaches.

Totally guided precision CT-based surgery is not a panacea to optimal implant positioning. Several key elements influence the ability to execute a desired treatment outcome. These include, but are not limited to: (1) quality of the CT imaging, including panoramic, cross-sectional, and axial 2D views; (2) reliability of the 3D reconstruction created by the radiology technician using the computer software; (3) quality of the

rapid-prototype medical modeling; (4) the challenge of determining the accurate position of thin crestal bone, which often competes with other radiopaque structures (eg, teeth, scanning appliances); (5) regional anatomy characteristics; (6) dimensional stability of the stone cast that is optically imaged for tooth-supported cases; (7) accurate placement and stability of the scanning appliance at the time of imaging; (8) the extent of the radiation artifact; (9) movement and fit of the guide during surgical execution; and (10) the knowledge and experience of the clinician in CT analysis and interpretation.

The use of totally guided precision CT-based surgery offers the opportunity for minimally invasive implant surgery and the obvious clinical benefits of reduced pain and swelling associated with open flap techniques.¹⁶ A totally guided approach, however, is associated with the highest risk and demands the most attention to detail in all phases of treatment. The use of rapid-prototype medical modeling and computer-guided implant dentistry creates the unique ability to execute precise surgical outcomes, facilitates the fabrication of a dental prosthesis prior to surgery, and enables the delivery of provisional teeth on the day of surgery.

These technologic advances require cooperative and collaborative input from all those responsible for patient care. In reality, each clinician must determine the most appropriate diagnostic approach for a given situation. It is clear that this technology can play a valuable role in improving patient care and in reducing the likelihood of undesirable outcomes.

Acknowledgments

The authors would like to thank Materialise Dental and Biomet 3i for supporting this case series by supplying the guides, surgical instrumentation, and implant componentry.

References

1. Garg AK. Implant surgical templates in implant dentistry: NobelGuide. *Dent Implantol Update* 2007;18:25–28.
2. Balshi SF, Wolfinger GJ, Balshi TJ. Guided implant placement and immediate prosthesis delivery using traditional Brånemark System abutments: A pilot study of 23 patients. *Implant Dent* 2008;17:128–135.
3. Ganz SD. Use of stereolithographic models as diagnostic and restorative aids for predictable immediate loading of implants. *Pract Proced Aesthet Dent* 2003;15:763–771.
4. Tardieu P, Vrielinck L, Escolano E. Computer-assisted implant placement. A case report: Treatment of the mandible. *Int J Oral Maxillofac Implants* 2003;18:599–604.
5. Mandelaris GA, Rosenfeld AL. The expanding influence of computed tomography and the application of computer guided implantology. *Prac Proced Aesthet Dent* 2008;20:297–305.
6. Rosenfeld AL, Mandelaris GA, Tardieu PB. Prosthetically directed implant placement using computer software to ensure precise placement and predictable prosthetic outcomes. Part 1: Diagnostics, imaging, and collaborative accountability. *Int J Periodontics Restorative Dent* 2006;26:215–221.
7. Rosenfeld AL, Mandelaris GA, Tardieu PB. Prosthetically directed implant placement using computer software to ensure precise placement and predictable prosthetic outcomes. Part 2: Rapid prototype medical modeling and stereolithographic drilling guides requiring bone exposure. *Int J Periodontics Restorative Dent* 2006;26:347–353.
8. Rosenfeld AL, Mandelaris GA, Tardieu PB. Prosthetically directed implant placement using computer software to ensure precise placement and predictable prosthetic outcomes. Part 3: Stereolithographic drilling guides that do not require bone exposure and the immediate delivery of teeth. *Int J Periodontics Restorative Dent* 2006;26:493–499.
9. Tardieu P, Vrielinck L. Implantologie assistée par ordinateur: Le programme SimPlantSurgiCase et le SAFE System. Cas clinique: Mise en charge immédiate d'un bridge mandibulaire avec des implants transmuqueux. *Implant* 2003;19:15–28.
10. Sarment DP, Sukovic P, Clinthorne N. Accuracy of implant placement with a stereolithographic surgical guide. *Int J Oral Maxillofac Implants* 2003;18:571–577.
11. Sarment DP, Al-Shammari K, Kazor CE. Stereolithographic surgical templates for placement of dental implants in complex cases. *Int J Periodontics Restorative Dent* 2003;23:287–295.
12. Van Assche N, van Steenberghe D, Guerrero ME, et al. Accuracy of implant placement based on pre-surgical planning of three-dimensional cone-beam images: A pilot study. *J Clin Periodontol* 2007;34:816–821.
13. Van Steenberghe D, Malevez C, van Cleynebreugel J, et al. Accuracy of drilling guides for transfer from three-dimensional CT-based planning to placement of zygoma implants in human cadavers. *Clin Oral Implants Res* 2003;14:131–136.
14. Loubele M, Guerrero ME, Jacobs R, Suetens P, van Steenberghe D. A comparison of jaw dimensional and quality assessments of bone characteristics with cone-beam CT, spiral tomography, and multislice spiral CT. *Int J Oral Maxillofac Implants* 2007;22:446–454.
15. Di Giacomo GA, Cury PR, de Araujo NS, Sendyk WR, Sendyk CL. Clinical application of stereolithographic surgical guides for implant placement: Preliminary results. *J Periodontol* 2005;76:503–507.
16. Oh TJ, Shotwell J, Billy E, Byun HY, Wang HL. Flapless implant surgery in the esthetic region: Advantages and precautions. *Int J Periodontics Restorative Dent* 2007;27:27–33.